



Naugatuck's New Ride Tops Off Year of Rebuild



Naugatuck EMS took delivery of a refurbished ambulance in July. The 2019 Ford/Braun was the third ambulance obtained by the organization since it reorganized in August of last year. NEMS also purchased a brand new Ford Explorer Paramedic fly car last September. Only one type 2 ambulance and weathered fly car remain from the old fleet.

In addition to new vehicles, Naugatuck rebranded all vehicles, logos and staff uniforms to reflect the town colors of Garnet and Grey along with the high school mascot Greyhound.

"The past 12 months have been challenging and transformative for Naugatuck EMS", explained Chief Kyle Kelley. "Replacing three ambulances, equipment and onboarding 30 new employees is no small task".


Kelley went on to praise Naugatuck Mayor Pete Hess and the Naugatuck EMS board of directors for their role in resurrecting the struggling agency. "Before they got involved, NEMS was on the verge of collapse".

Later this month, Mayor Hess will be recognized by the Regional Chamber of Commerce's Healthcare Council for his role in providing the leadership and resources that led to the rescue and revitalization of NEMS. "Pete definitely deserves the recognition. What he did for us is immeasurable", said Kelley.

Upcoming CMEs

September 21st 2022 @ 6:00 P.M.

Topic: **"Neonatal/Pediatric Emergencies"**
Brooke Redmond, MD, FAAP, IBCLC, CHSE
Waterbury Hospital
Assistant Professor & Medical Director
Neonatal Intensive Care Unit
Chair of Pediatrics
Neonatal - Perinatal Medicine



October 19th 2022 @ 6:00 P.M.

Topic: **"Trauma Management of the Obese Patient"**
Juan Diego Holguin, MD
Chief, Section of Surgery
Faculty-General Surgery Residency Program
Advanced Laparoscopic & Robotic Surgery



November 16th 2022 @ 6:00 P.M. - 9:00 P.M.

Special Session: "Assessment & Treatment of the Ventricular Assist Device (VAD) Patients"

Learn & Review the Mechanics/Treatment Modalities for VAD Patients
Kelly McNamara - Diorio
Registered Nurse, VAD Coordinator
Abbot Laboratories

Reminder

All Waterbury Hospital CMEs are video recorded and available for viewing and CME credit on the hospital website, waterburyhospital.org.

CMEs are open to all levels of EMS providers and affiliations. Dinner is served at Waterbury Hospital CMEs.

Recognizing Excellence in Pre-Hospital Care

Trauma

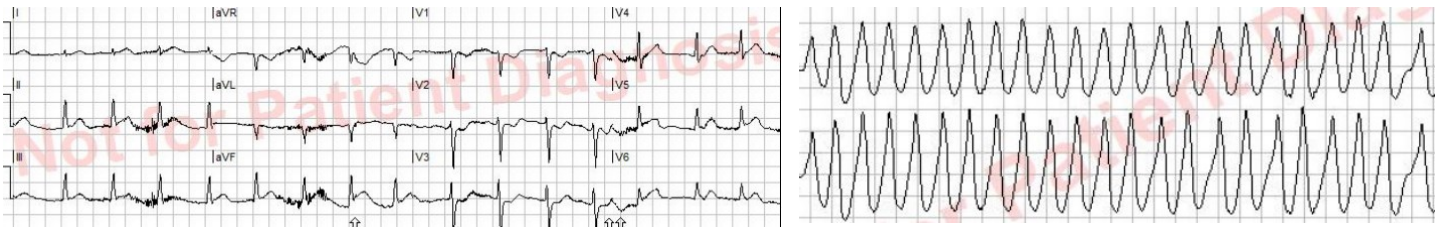Bulldozer Accident in the woods resulted in a male sustaining multiple traumatic injuries to the ribs, lower back, pelvis and lower extremity.

Patient was alone at the time of the incident. Fortunately, a friend passed by the site and activated the 911 System. Multiple agency response is credited with saving patient from loss of life and limb. Connecticut State Police as well as **Roxbury Fire/EMS** responded to the scene and activated a **Trauma Alert** to Waterbury Hospital. Roxbury EMS Chief Sarah Lauriat and crew members Ashley Conway, Aaron Hodge, Tracey Cahill, Kaye Collins, Bill Brockett, Brien Cartegna assisted with stabilizing patient for transport from the woods. Roxbury Volunteer Fire Department members Bill Steers, Ken Murphy, Russ Wheeler, Jerome Vidal, Paul Swanson, James Loswe and Mark Maynard also assisted with the extraction from the woods to the awaiting ambulance.

Trinity Medic 4 also assisted with initial stabilization in the field. Woodbury Fire Chief Janet Morgan provided additional resources. On arrival to Waterbury Hospital patient was administered *Normal Saline Fluid Boluses* and *Packed Red Blood Cells (PRBC)* given via rapid infuser due to peri-arrest status. AMR Paramedic Corey Rymer and EMT Stefanie Carpentier assisted with transfer from Waterbury Hospital to the Helipad for transfer via Helicopter after stabilization by Emergency Department Staff & Trauma Team. Great Teamwork! Patient is recovering from injuries!

Cardiopulmonary Arrest with ROSC

Waterbury Fire Department & AMR EMTs Adrien Edwards, Danielle Erwin, Michael Messenger and Paramedic John Racloz successfully resuscitated a middle-aged female sustaining out of hospital cardiopulmonary arrest. After several defibrillations EMS converted **Pulseless Ventricular Tachycardia** to a perfusing rhythm. Paramedic Racloz activated a **STEMI Alert** with **ROSC**. Cardiogenic Shock Status was stabilized. Cath Team found a 100% occlusion of the Mid-Left Circumflex Artery and 80% Sequential Lesions of the Right Coronary Artery. Percutaneous Coronary Intervention/Coronary Angioplasty was performed with patient recovering well. Strong work on the part of the all working together!



ST-Elevation Myocardial Infarction (STEMI) ALERTS

Southbury Ambulance Association activated a STEMI Alert from the field and transmitted an ECG indicating an **Inferior Wall Myocardial Infarction** to Waterbury Hospital Emergency Department. Cath Lab was immediately activated and a PCI and Thrombectomy of the Right Coronary Artery was successfully performed. Patient was discharged home to family and is recovering well thanks to the efforts of Pre-Hospital EMS & Waterbury Hospital Staff.

Naugatuck EMS EMTs Andrew Drake, Sarah Sullivan with Paramedic Robert Daley activated a **STEMI** Alert for an Inferior Wall Myocardial Infarction with Cardiogenic Shock Status. Patient complaining jaw pain, nausea, dizziness with near syncope. Paramedic Daley keenly advised Emergency Department Physician regarding subtle changes noted in the 12 ECG Tracing prompting activation of the Cath Lab Team. PCI was successfully performed and patient was discharged to family and is doing remarkably well.